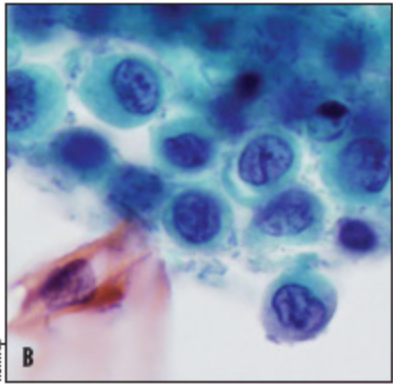
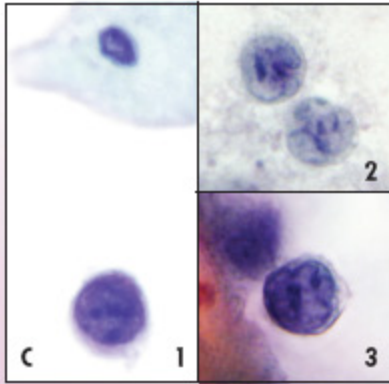


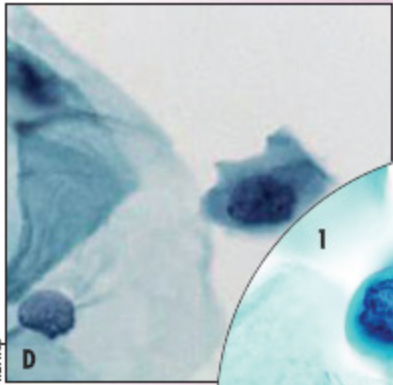
Fig. 8. HSIL: Single small cells



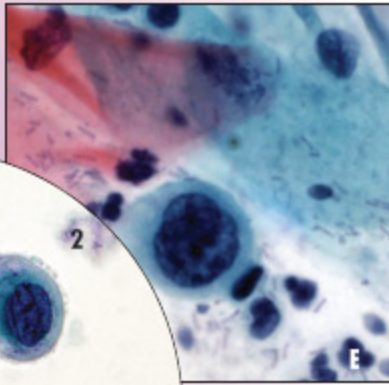
Histiocytes: Exodus



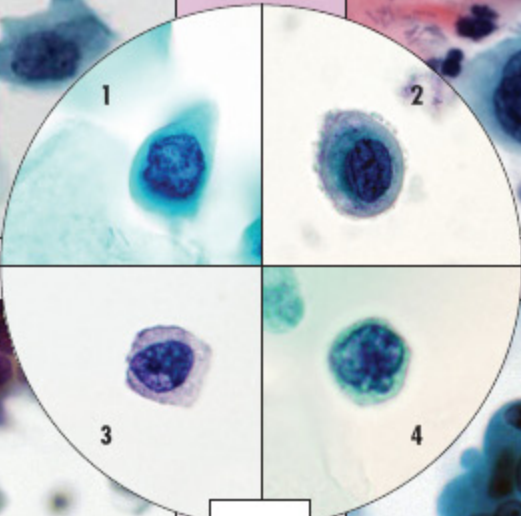
1. Lymphocyte, germinal center cell; 2,3. Lymphoma



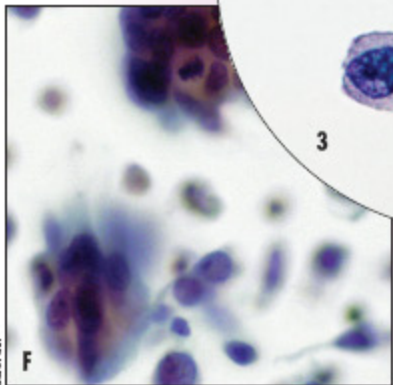
Squamous metaplasia



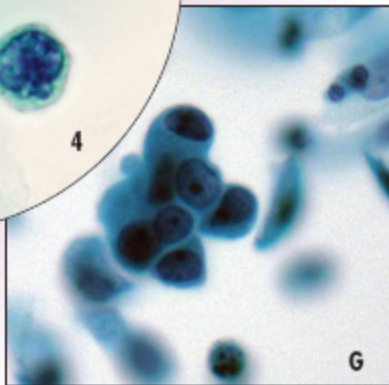
Intrauterine device



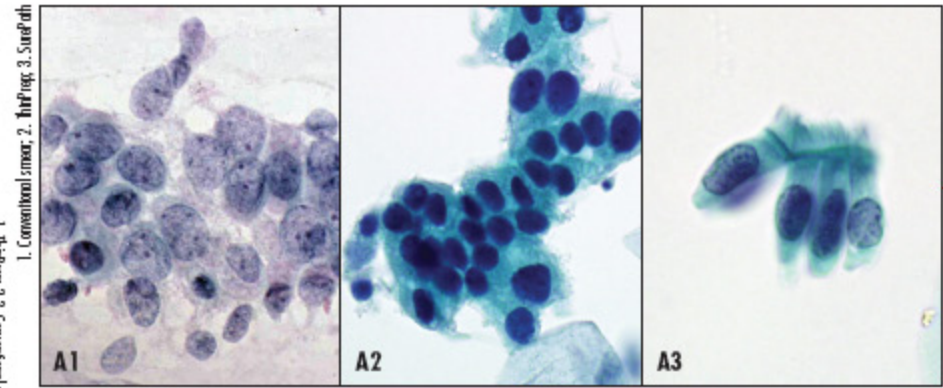
▲  
A. HSIL  
1,4. SurePath  
2,3. ThinPrep



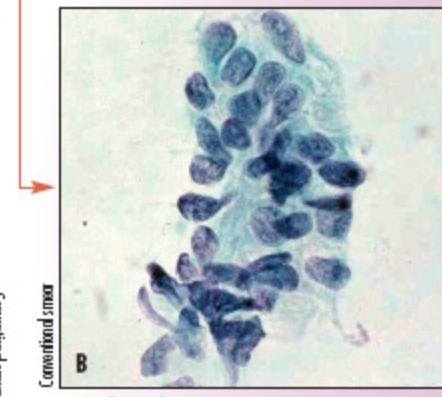
Adenocarcinoma in situ



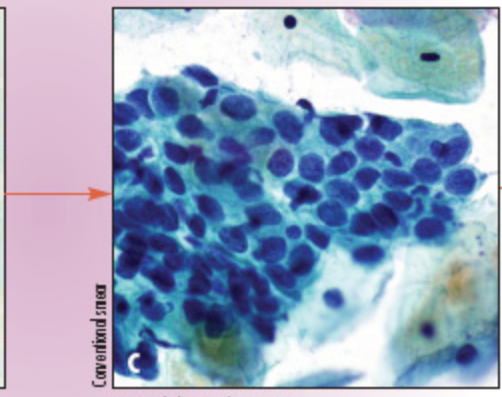
Metastatic breast carcinoma



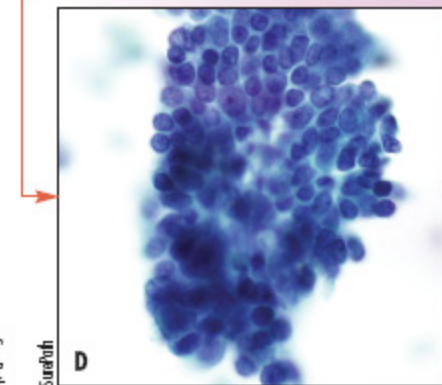
Tubal metaplasia (TM)



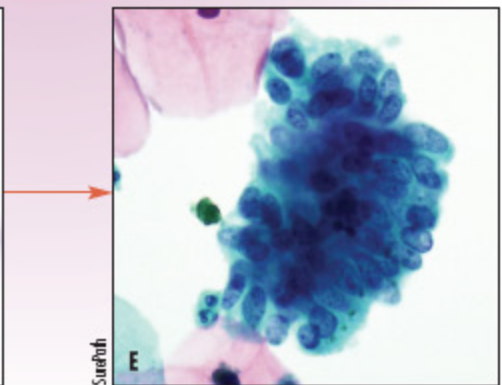
TM without cilia



TM with hyperchromasia



Tuboendometrial metaplasia



TM with AIS features