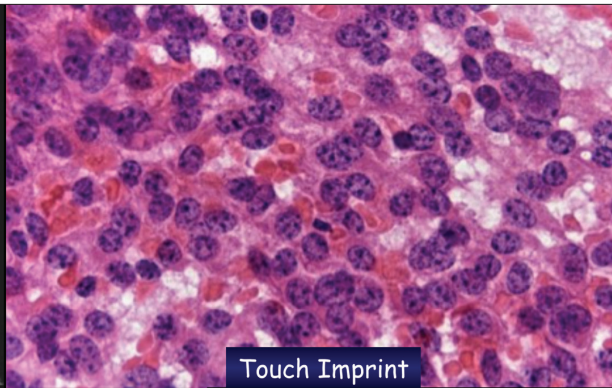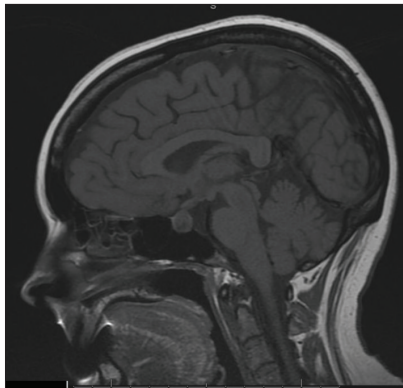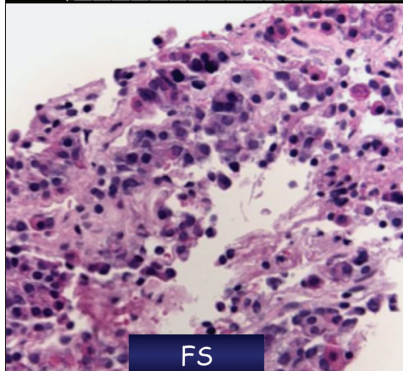
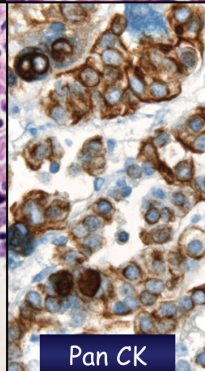


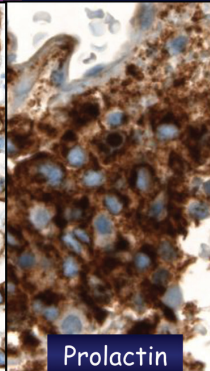
Touch Imprint



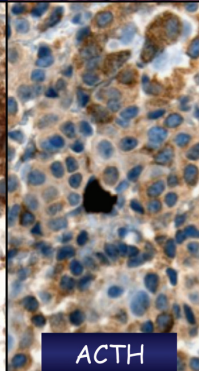
FS



Pan CK



Prolactin



ACTH

Sample images from a pituitary adenoma case with imprint cytology, courtesy of Walid Khalbuss, MD, PhD.