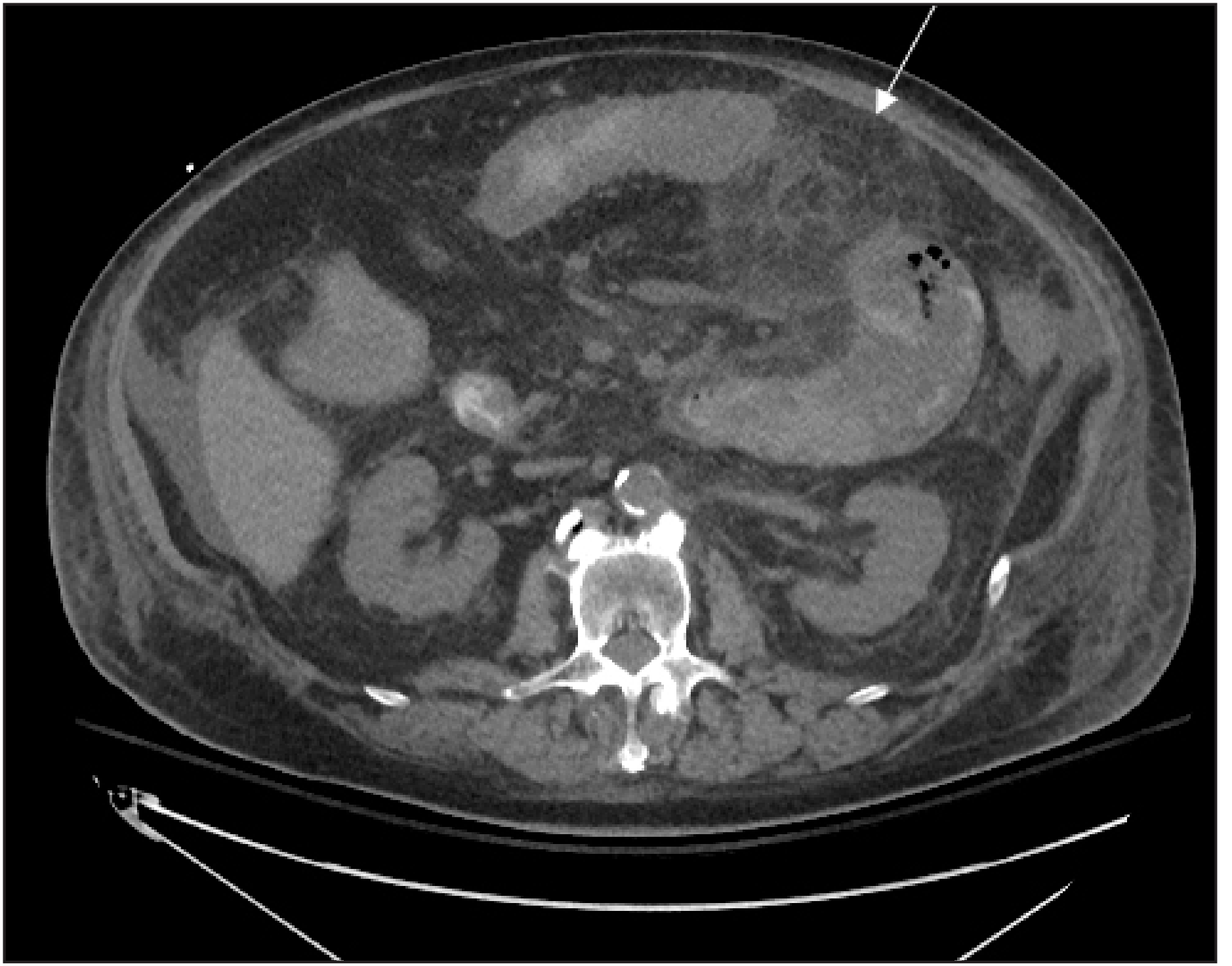

Fig. 1. Abdominal CT showing small bowel with minimal residual lumen and mucosal thickening surrounded by extensive inflammatory mesenteric fat stranding.