

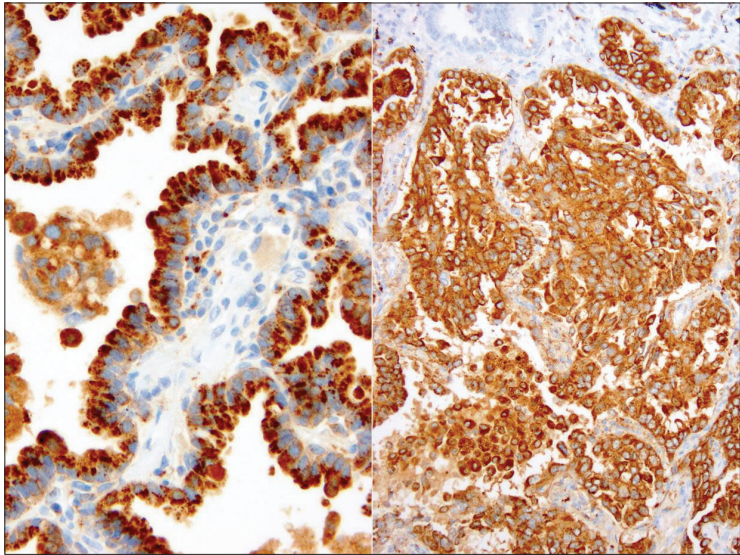Fig. 1. Composite photograph of napsin A staining in a pulmonary adenocarcinoma. The figure on the left displays the granular cytoplasmic pattern seen with this marker.

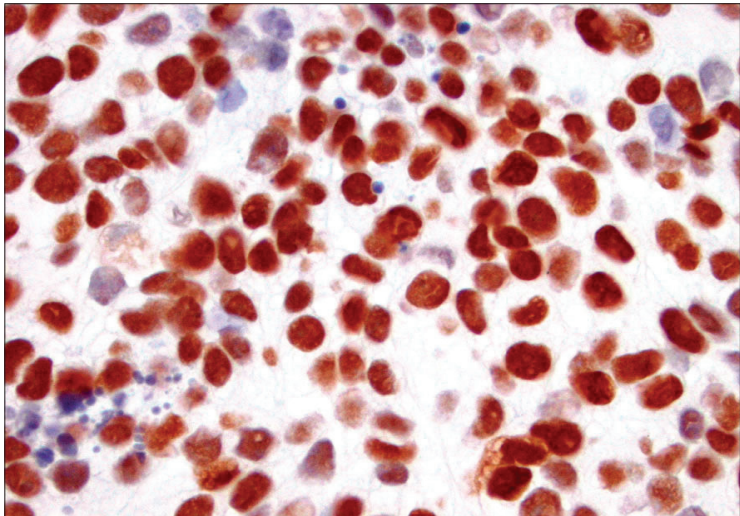


Fig. 2. p63 staining in a cytology cell block preparation. Note the sharp nuclear stain confirms the squamous origin of this non-small cell lung carcinoma.