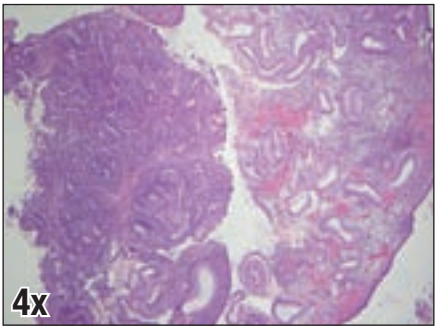

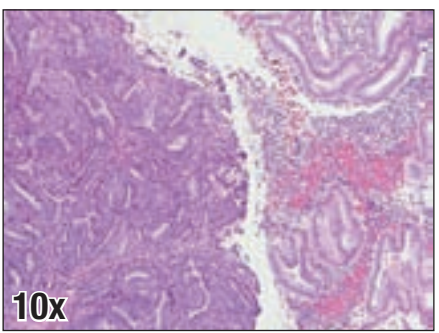

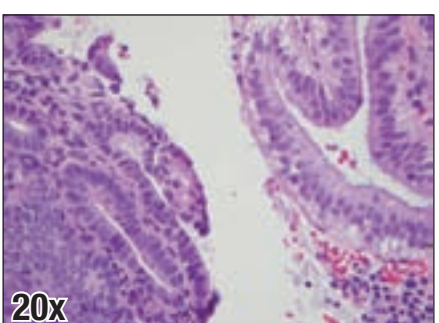

Endometrial hyperplasia in secretory endometrium, from an endometrial biopsy specimen from a 45-year-old. Women and Infants Hospital of Rhode Island.