

# A new case of severe hemophilia and Moyamoya (SHAM) syndrome

**Colleen G. Bilancia, PhD**

**Hemant Varma, MD**

**Vimla Aggarwal, MBBS**

**August 2016**—CAP TODAY and the Association for Molecular Pathology have teamed up to bring molecular case reports to CAP TODAY readers. AMP members write the reports using clinical cases from their own practices that show molecular testing's important role in diagnosis, prognosis, and treatment. The following report comes from Columbia University Medical Center. If you would like to submit a case report, please send an email to the AMP at [amp@amp.org](mailto:amp@amp.org). For more information about the AMP and all previously published case reports, visit [www.amp.org](http://www.amp.org).



Hemophilia is a rare bleeding disorder caused by deficiency in clotting factors. Clinical features include prolonged or excessive bleeding after injury, easy bruising, pain and swelling in joints, hematuria, hematochezia, and nosebleeds. Hemophilia is a genetic disorder and there are several types. Hemophilia A (No. 306700 in the Online Mendelian Inheritance in Man, or OMIM, database) is the most common and caused by genetic mutations in coagulation factor VIII (OMIM: 300841). Hemophilia B is the second most common and caused by genetic mutations in coagulation factor IX. Hemophilia C is milder and caused by genetic mutations in coagulation factor XI. Hemophilia A and B are X-linked while hemophilia C is autosomal (long arm of chromosome 4). Normal platelet count and prothrombin time with a prolonged activated partial thromboplastin time are typical findings for a diagnosis of hemophilia A and B. Testing for specific clotting factor deficiencies can then separate the types and lead to a definitive diagnosis.

Diagnosis of hemophilia usually occurs by age two. Treatment for moderate to severe cases includes prophylactic clotting factor injects, injury/surgery avoidance, and prompt treatment of acute injuries. Here we present a case of a patient with severe hemophilia A, which was further complicated by Moyamoya, a disease involving intracranial carotid artery occlusions.

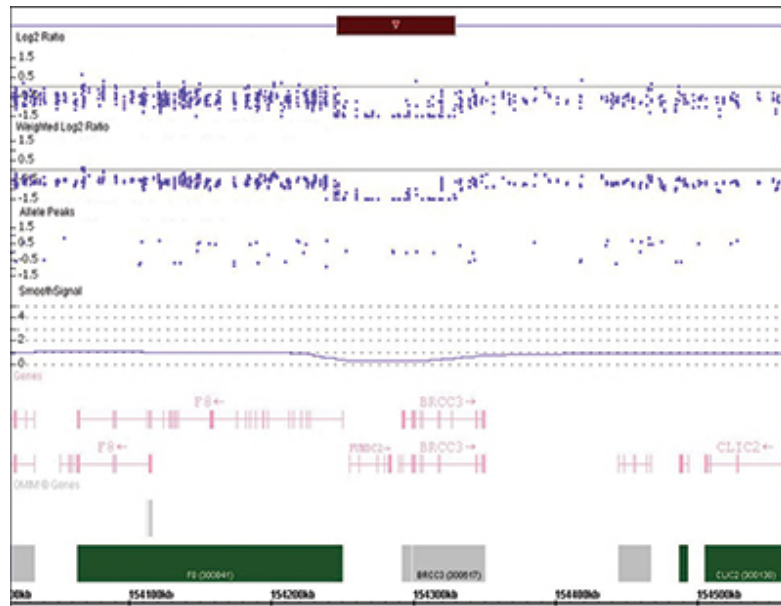
**Patient case.** The patient is a 22-year-old male with hemophilia A, factor VIII levels historically in the range of zero to one percent, and a clinical history consistent with a severe hemophilia phenotype. The patient is hypertensive, has mild left ventricular hypertrophy, chronic arthropathy of the left elbow, and left kidney cysts. The patient was also noted to be macrocephalic and of short stature with unspecified developmental delays. Treatment consists of prophylactic factor VIII of 20 U/kg three times a week and 10 mg lisinopril daily for hypertension. Patient is followed regularly to monitor hypertension, factor VIII levels, and any acute injuries that need medical attention.

The patient presented to the emergency department after an unwitnessed syncopal episode, and he became lethargic, diaphoretic, and unresponsive during triage. On CT imaging an acute right frontal temporal extra-axial hemorrhage with right-to-left shift was identified. Craniotomy was performed to remove the subdural hematoma. The patient remained in the hospital for five months due to complications from seizures and pneumonia.

A month after admission, the patient had an intracranial hemorrhage that required a right frontal lobectomy. Upon histological examination of the resected brain tissue, there was evidence of a resolving hematoma in the subarachnoid space and a subacute infarction involving the right frontal cortex and white matter. The subacute infarction was evident by necrotic brain tissue infiltrated by abundant macrophages and activated microglia, and was accompanied by proliferative capillaries. Also noted were penetrating vessels with thickened adventitia and thinning media, and focal disruption of elastic lamina of a larger blood vessel. Subsequent cranial angiogram

showed these vascular changes were consistent with a diagnosis of Moyamoya disease.<sup>1</sup>

Moyamoya disease is a disorder of the cerebral vasculature, with bilateral occlusion of the intracranial carotid artery associated with telangiectatic vessels in the basal ganglia (OMIM:252350). Diagnosis is based on these findings in a cerebral angiography or magnetic resonance angiography. The name results from the Japanese word used to describe the angiographic findings, which resemble a puff of smoke. Patients with Moyamoya disease may present differently depending on the age of onset. Childhood cases usually present with epileptic seizures or acute hemiplegia, whereas subarachnoid bleeding is more common in adult cases. Treatment for Moyamoya disease may involve antiplatelet medication or surgery to revascularize the affected areas, both of which pose a significant risk for a hemophilic patient.



**Fig 1.** Chromosomal microarray result showing 83 kilobase interstitial deletion on Xq28. Xq28 deletion and normal flanking regions in the patient and his sister. The copy number state shows a red bar indicating the area of loss on chromosome X. The Log2 Ratio, Weighted Log2 Ratio, and Allele tracks show loss of signal in the region from positions 154,246,916-154,329,983 (GRCh37/hg19). In this case there is one copy of the flanking regions but zero copies in the 83 kilobase deletion. The smooth signal gives a best fit for the array data across that region. Genes are listed below the data tracks and show that the 5' regions of *F8* and *BRCC3* are lost. *FUNDC2*, *MTCP1*, and *CMC4* are fully removed by the deletion. The genomic coordinates and chromosomal position are listed at the bottom.

Given the complicated clinical picture for the patient involving both hemophilia and Moyamoya disease, he was counseled and consented to a genetic workup to identify any underlying genetic cause. Results of the genetic testing showed a 46,XY normal male karyotype. Chromosomal microarray testing showed a submicroscopic deletion on the long arm of X chromosome. The deletion is interstitial at Xq28 and is 83 kilobases in size, from positions 154,246,916-154,329,983 (GRCh37/hg19). The region contains five genes (*F8*, *FUNDC2*, *CMC4*, *MTCP1*, and *BRCC3*), three of which are listed in OMIM: *F8* (OMIM: 300841), *MTCP1* (OMIM: 300116), and *BRCC3* (OMIM: 300617, **Fig. 1**).

*F8* is coagulation factor VIII and the deletion removes the 5' coding region of the gene, causing its disruption and the severe hemophilia in the patient. The deletion also disrupts *BRCC3*, a deubiquitinating enzyme that is part of the BRCA1/BRCA2-containing complex. It has been shown that *BRCC3* mutations are the causative gene for

Moyamoya disease features for MoyaMoya4 locus on chromosome Xq28.2,3 Furthermore, deletions involving this region and including all three genes have been implicated in a new disease referred to as Severe Hemophilia and Moyamoya (SHAM) syndrome (OMIM: 300845).<sup>4</sup> In addition to the defining clinical features of hemophilia and Moyamoya, people with SHAM are of short stature, have dysmorphic features, and may develop cardiomyopathy and left ventricular enlargement. For this patient, genetic testing identified an 83 kilobase deletion on the X chromosome and revealed a single underlying genetic cause for his clinical manifestations. These findings provide crucial information for his clinical management in the future.

After the deletion was identified, the patient received additional genetic counseling and familial testing was offered. The patient's sister decided to pursue genetic testing because she was concerned about her reproductive risk and has a history of postsurgical bleeding and easy bruising, common symptoms for female carriers of hemophilia. Genetic testing showed that she is a heterozygous carrier for the Xq28 deletion found in her brother. She received genetic counseling and was informed of the risk of passing the deletion to her children. Because the deletion is on the X chromosome, there is a 50 percent chance that a son would be affected. For daughters, there is a 50 percent chance that they, like their mother, would be a carrier.

The patient and his sister have the same Xq28 deletion, suggesting they inherited it from their mother; however, germline mosaicism is still possible. The patient's mother was not available for genetic testing, but the patient reports that she had easy bruising and his maternal uncle had hemophilia and died at age four. Given the mother is symptomatic and has an affected son and brother, she fits the criteria for an obligate carrier. These findings make germline mosaicism unlikely and show that the Xq28 deletion is a familial mutation.

**Discussion.** Genetic testing in this patient at an earlier age would have been advantageous. The X chromosome deletion provides an understanding of the severe hemophilia phenotype of the patient, which can help in clinical management. In addition, genetic testing identified disruption of genes in addition to coagulation factor VIII. BRCC3 is known to be the causative gene for Moyamoya disease 4. Although treatment options have been disappointing for Moyamoya disease, an earlier genetic diagnosis would have allowed for better monitoring and clinical management of the disorder. Finally, familial testing provided important carrier status information and counseling to the patient's sister, which will be beneficial in family planning.

1. Yamashita M, Oka K, Tanaka K. Histopathology of the brain vascular network in moyamoya disease. *Stroke*. 1983;14(1):50-58.
2. Hervé D, Touraine P, Verloes A, et al. A hereditary moyamoya syndrome with multisystemic manifestations. *Neurology*. 2010;75(3):259-264.
3. Miskinyte S, Butler MG, Hervé D, et al. Loss of BRCC3 deubiquitinating enzyme leads to abnormal angiogenesis and is associated with syndromic moyamoya. *Am J Hum Genet*. 2011;88(6):718-728.
4. Janczar S, Fogtman A, Koblowska M, et al. Novel severe hemophilia A and moya-moya (SHAM) syndrome caused by Xq28 deletions encompassing F8 and BRCC3 genes. *Blood*. 2014;123(25):4002-4004.

[hr]

*Dr. Bilancia is a clinical cytogenetics and molecular genetics fellow, Dr. Varma is a molecular genetic pathology fellow, and Dr. Aggarwal is an assistant professor of pathology and cell biology—all in the Department of Pathology and Cell Biology, Columbia University Medical Center, New York, NY.*